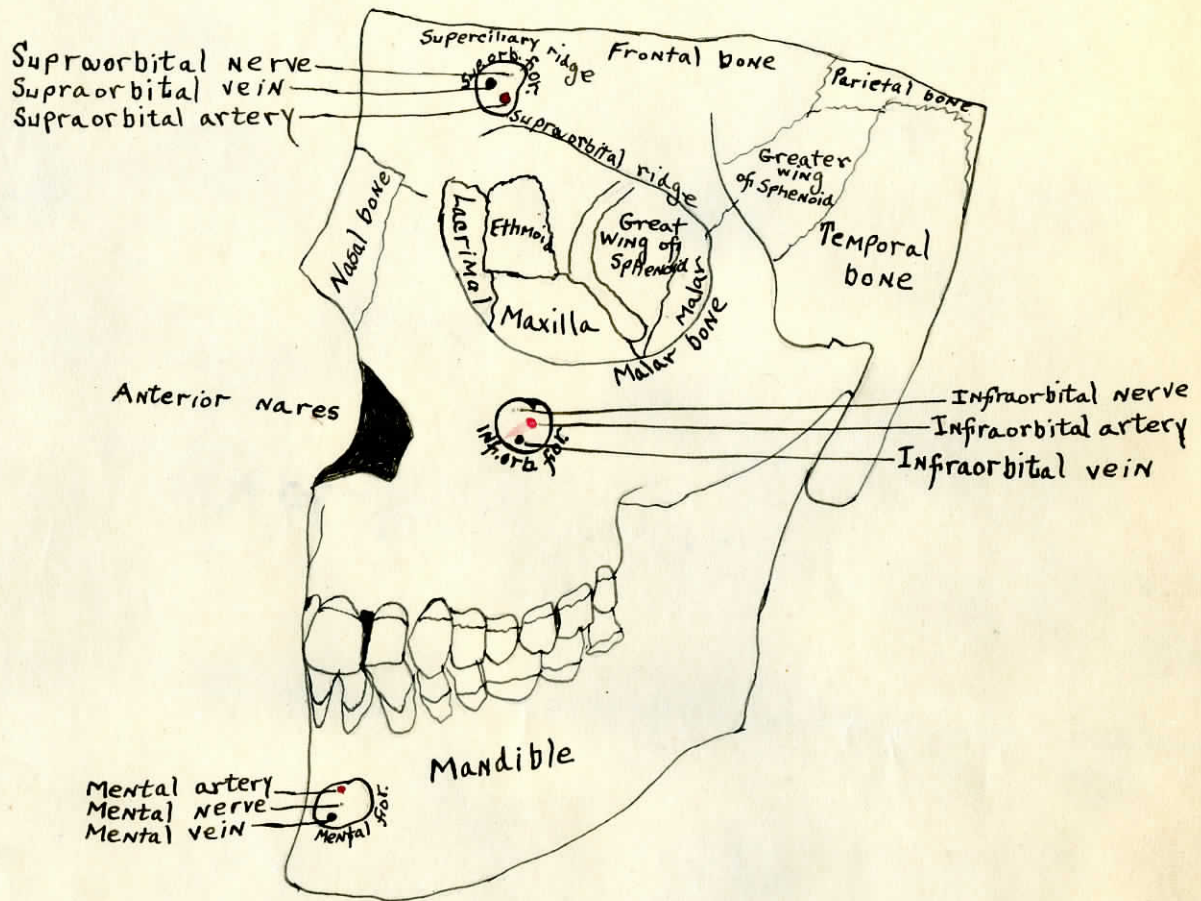


March 9, 1922.



Drawing of skull showing face and three openings, supraorbital, infraorbital, and mental with respective vessels and nerve.